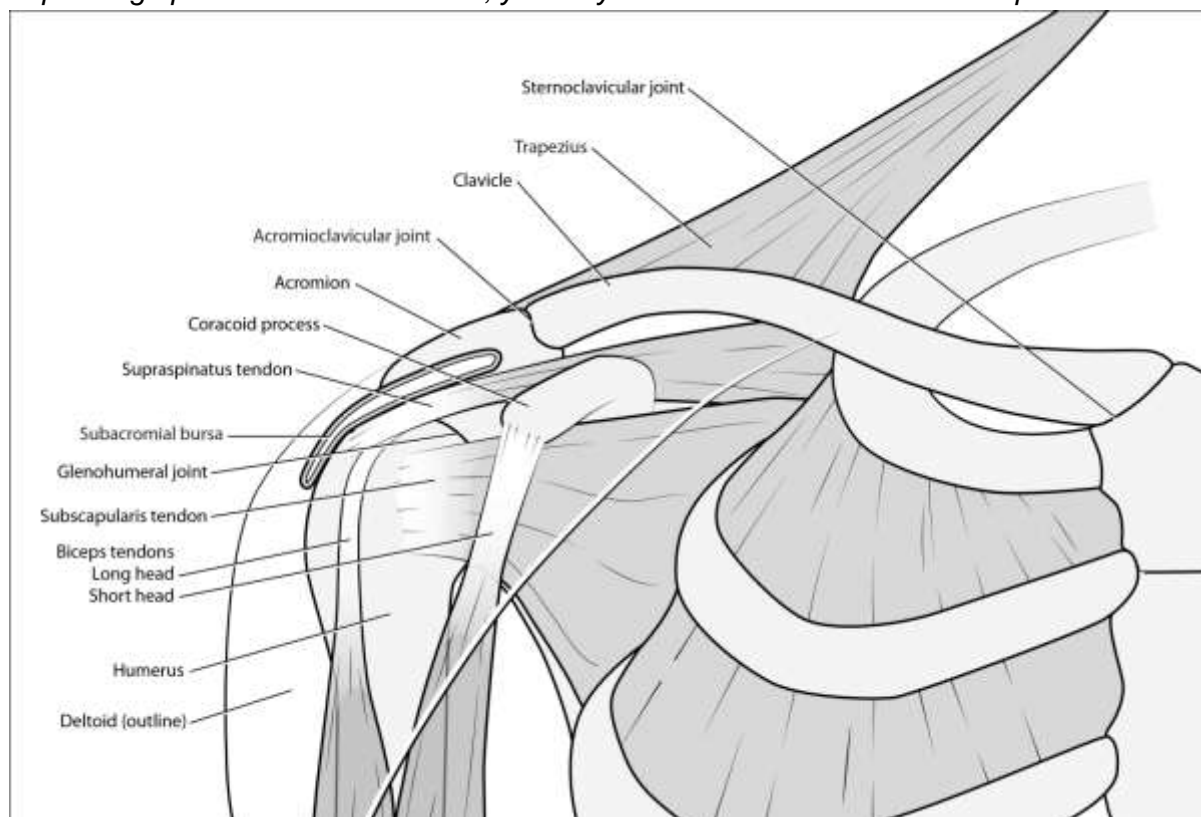


SHOULDER EXAMINATION

Depending upon the clinical scenario, you may need to examine the cervical spine and elbow.



INSPECTION

- Swelling (especially joints)
 - Sternoclavicular
 - Acromioclavicular
 - Glenohumeral (bulge at delto-pectoral groove may occur in very large effusions)
- Erythema
- Atrophy
 - Pectoralis major
 - Deltoid (causing squaring of shoulder)
 - Supraspinatus and infraspinatus
 - Trapezius
- Deformities
 - Step-deformity of the clavicle (prior fracture)
 - Step-deformity of acromioclavicular joint (AC ligament disruption)
 - Asymmetrical height of shoulders
 - *May be from scoliosis or Sprengel's deformity (high riding scapula)*
 - Shoulder elevation, depression, protraction, or retraction
 - Winging of scapula
 - *Ask the patient to "do a push up against wall"*

- *Winging is caused by injury of long thoracic nerve and paralysis of serratus anterior muscle*

PALPATION

- Palpate the sternoclavicular, acromioclavicular and glenohumeral joints for warmth
- Then systematically palpate the bones and soft-tissue structures for tenderness
- SC joint, clavicle, coracoid process, AC joint, acromion, spine of scapula
- Trapezius, supraspinatus, infraspinatus, deltoid, triceps, biceps muscles
- Long and short head of biceps
- Rotator cuff insertion on greater tuberosity of humerus (extend arm backwards to bring humerus out from under the acromion)
- Palpate for crepitus during shoulder movement

RANGE OF MOVEMENT

Generally perform active ROM first, followed by passive ROM if active ROM is limited. These may be integrated at terminal range of movement.

- **Active ROM**
 - Abduction (180°)
 - Look for painful arc (pain typically between 60-120°)
 - Found in subacromial impingement, subacromial bursitis, supraspinatus tendonitis
 - If pain begins beyond 120°, this may indicate AC joint pathology
 - Scapulothoracic Rhythm
 - First 30°: movement at glenohumeral joint
 - Beyond 30°, scapula engages with a 2:1 ratio of glenohumeral to scapulothoracic movement
 - With adhesive capsulitis, the humerus and scapula move together as one complex
 - Adduction
 - *Cross arms in front of body*
 - Flexion (180°)
 - Extension (60°)
 - External Rotation
 - *Arms at sides, flex elbows to 90°, rotate forearms away from body*
 - Normal is 45-90° in this position
 - Internal Rotation
 - *Arms at sides, flex elbows to 90°, rotate forearms into body and behind back*
 - Normal up to 120°
 - Apley Scratch Test
 - *Ask patient to touch tip of opposite scapula*
- **Passive ROM**
 - Perform if active range of motion is restricted
 - Adhesive capsulitis will result in global restriction in all fields of movement
 - Check for crepitus (hand over shoulder, move arm around)

POWER ASSESSMENT

Best done by resisted isometric testing, with patient resisting examiner's force

- With arms at side, elbow flexed to 90°
 - Flexion
 - Extension
- Arms abducted from sides at approximately 20°
 - Abduction
 - Adduction

SPECIAL TESTS

- **Supraspinatus tear**
 - Drop Arm Test
 - *Assessed during abduction, as the patient actively brings arms back to sides from an overhead abducted position*
 - *If the arm suddenly drops to side, this indicates a torn supraspinatus*
 - *Alternatively, with the arm abducted to 90°, quickly “chop” down on the arm*
 - *If arm suddenly drops to side, this indicates a torn supraspinatus*
- **Subacromial Impingement Syndrome** (or Supraspinatus tendonitis, or Subacromial bursitis)
 - Painful Arc
 - *Look for painful arc (pain typically between 60-120°)*
 - Neer's Test (done passively)
 - *With elbow in full extension, stabilize the shoulder and lift the arm to the ear (Neer's to the ear)*
 - *Pain is a positive test*
 - Hawkins-Kennedy Test
 - *Shoulder flexed forward to 90° ad elbow flexed 90° with forearm parallel to floor*
 - *Passively rotates the forearm clockwise (causing internal rotation at the shoulder)*
 - *Pain indicates a positive test*

Evidence-Based Medicine: Subacromial Impingement (SIS), including subacromial bursitis and supraspinatus/rotator cuff tendonitis

Neer's Test

Sensitivity 78%, Specificity 58%
Diagnostic Value: Ruling out SIS

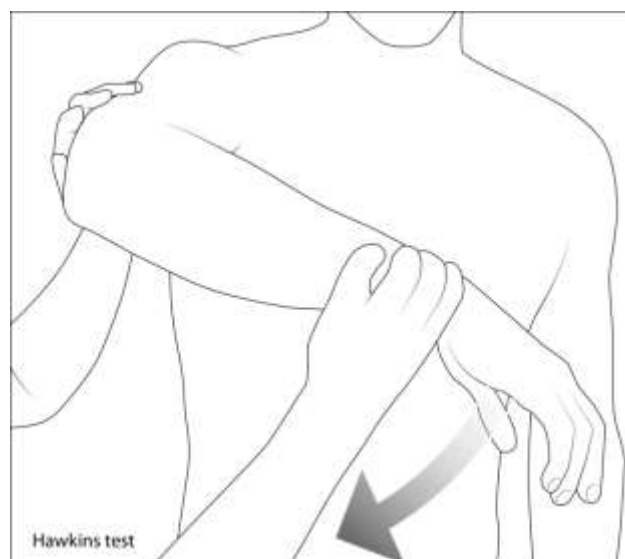
Hawkins-Kennedy Test

Sensitivity 74%, Specificity 58%
Diagnostic Value: Ruling out SIS

Empty Can Test

Sensitivity 69%, Specificity 62%
Diagnostic Value: Ruling in SIS

Arch Phys Med Rehabil. 2012 Feb;93(2):229-36.



- Empty Can Test
 - Arms abducted 45° and flexed forward 45° (as if emptying a can), thumbs pointing down
 - Patient resists examiner's downward pressure on arms
 - Pain at the tip of the shoulder is a positive test

- **Bicipital Tendinitis**

- **Speed's Test**
 - Elbow extended, arm supinated and forward at 45°
 - Patient resists downward pressure from the examiner
 - Pain at the biceps tendon indicates bicipital tendinitis
- **Yergason's Test** (resisted supination)
 - Patient's arm at side, elbow flexed at 90°, and hand in neutral position
 - Hold the patient's wrist and attempt to pronate the forearm, with the patient resisting by trying to supinate
 - Pain at the biceps tendon indicates bicipital tendinitis

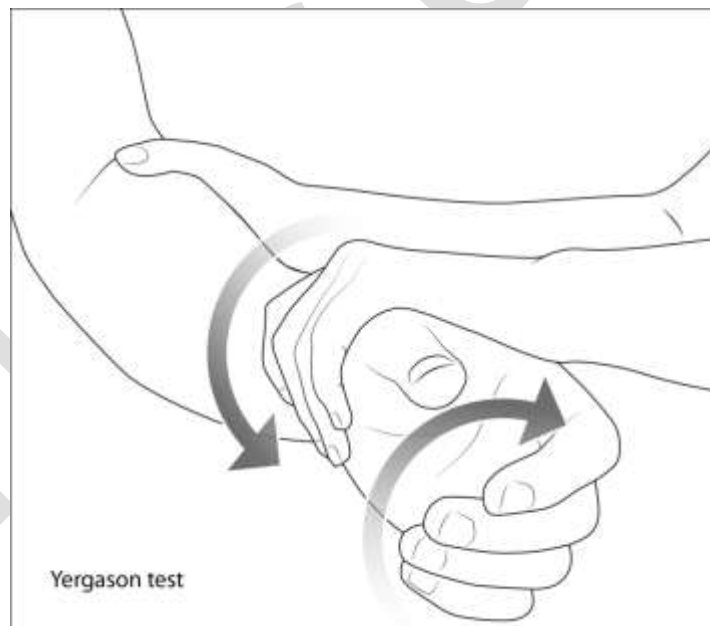
Evidence-Based Medicine: Bicipital Tendinitis

Speed's Test

Sensitivity 90%, Specificity 113.8%

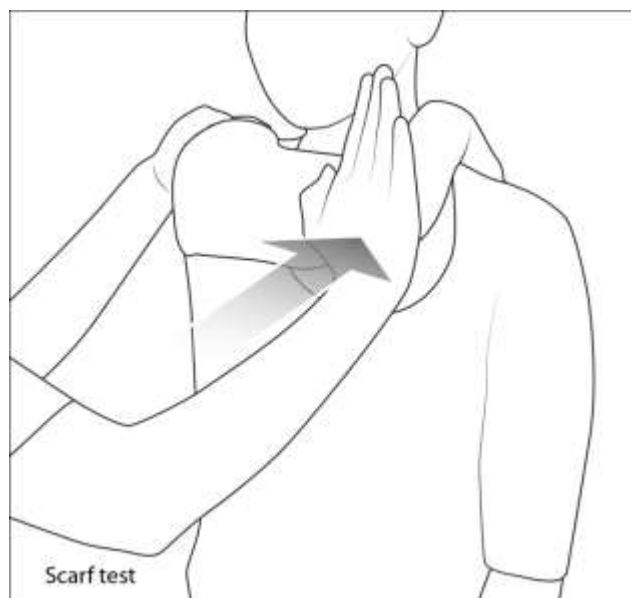Diagnostic Value: Ruling out bicipital tendinitis

Bennett, Arthroscopy 1998 Nov-Dec;14(8):789-96



- **AC Joint Pathology**

- **Scarf Test (AC Joint Compression Test)**
 - Patient places hand on the opposite shoulder
 - Examiner then pushes arm into the body, while stabilizing the opposite shoulder
 - Pain around the acromioclavicular joint suggests acromioclavicular pathology e.g. osteoarthritis



- **AC Joint Distraction Test**
 - Patient adducts the arm behind the back, with the dorsum of their hand resting on the opposite buttock
 - Apply additional adduction force while stabilizing at the opposite shoulder
 - Pain at the acromioclavicular joint suggests acromioclavicular pathology
- **Shoulder Instability**
 - **Sulcus Sign** (inferior instability)
 - With the opposite shoulder stabilized, apply downward pressure on the arm by grasping just above the elbow
 - Appearance of a sulcus at the tip of shoulder indicates inferior instability
 - **Anterior and posterior instability**
 - Attempt to move the head of the humerus backwards and forwards
 - Excessive movement indicates anterior (movement forwards) or posterior (movement backwards) instability
 - **Apprehension Test** (anterior subluxation)
 - With the patient lying supine, passively abduct and externally rotate the arm at 90°
 - With one hand holding the wrist, apply upwards pressure against the head of the humerus in an anterior direction to pull the humeral head forward
 - If the patient becomes apprehensive and complains of pain, this is indicative of recurrent anterior subluxation
 - **Relocation Test** (anterior subluxation)
 - Continuing from the Apprehension Test, apply downward pressure on the head of humerus
 - If the patient becomes relaxed and looks relieved, this is a positive relocation test for recurrent anterior subluxation
 - **Anterior Release Sign** (anterior subluxation)
 - Continuing from the Relocation Test, suddenly remove the posterior force
 - If the patient again looks apprehensive and complains of pain, this is a positive anterior release sign for recurrent anterior subluxation

Evidence-Based Medicine: Shoulder Instability

Sulcus Sign

Sensitivity 31%, Specificity 89%

Diagnostic Value: Ruling in inferior shoulder instability
T'Jonck et. al. Geneeskunde Sport 2001;3415-24

Anterior Relocation Test

LR+ 6.5, LR- 0.18

Diagnostic Value: Ruling in anterior shoulder instability
Luime JJ et al. 2004. JAMA 292(16): 1989-1999

Anterior Release Sign

LR+ 8.3, LR- 0.09

Diagnostic Value: Ruling in anterior shoulder instability
Luime JJ et al. 2004. JAMA 292(16): 1989-1999